

# Pediatric Whole Body Phantom "PBU-70"

This phantom is easy to handle for positioning, and provides complete bone images for every joint.

Pediatric Whole Body Phantom is modeled after a 5-year-old child of 105cm (43") in height. This is a life-size, full body anthropomorphic phantom with a state-of-the-art synthetic skeleton, lungs, liver mediastinum and kidneys. Its movable and detachable joints allow various positioning.

## Features

1. Movable joints allow basic positioning for plain X-ray.
2. Training and research applications can be enriched by disassembling the phantom into 10 individual parts (head, limbs and trunk).
3. Main joints have life-like articulation, allowing various positioning for training.
4. The phantom has no metal parts or liquid structures.
5. No deficit in bone images of joints.



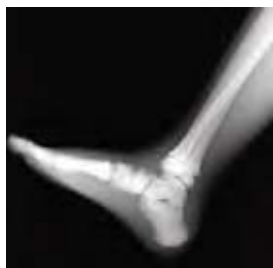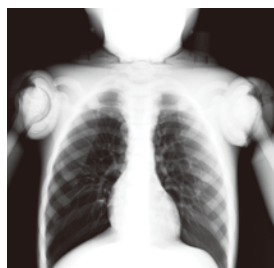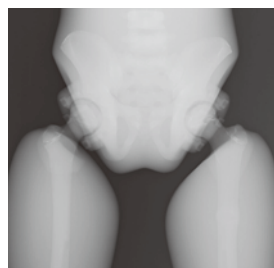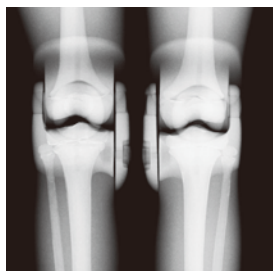
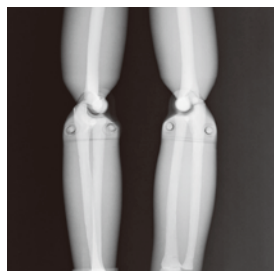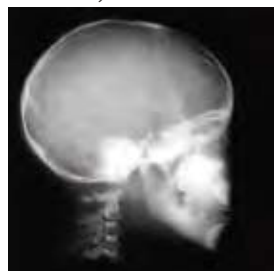## Training Skills

- Plain X-ray photography and basic CT scanning
- Basic patient positioning for X-ray and CT

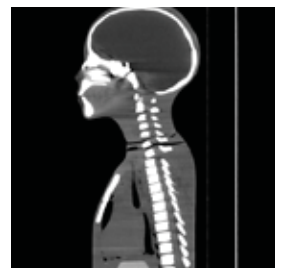
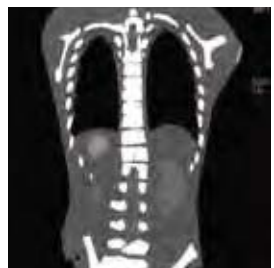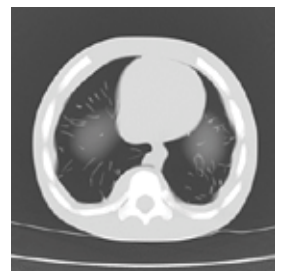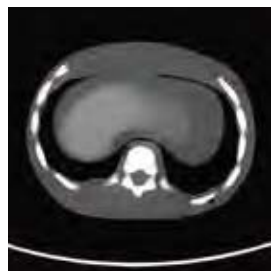## Anatomies

- Full synthetic skeleton
- Main pulmonary vessels, mediastinum, liver, kidneys

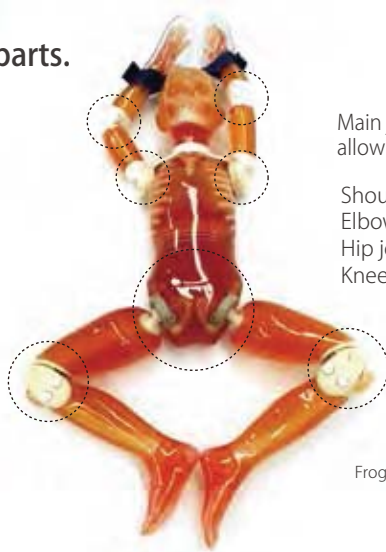
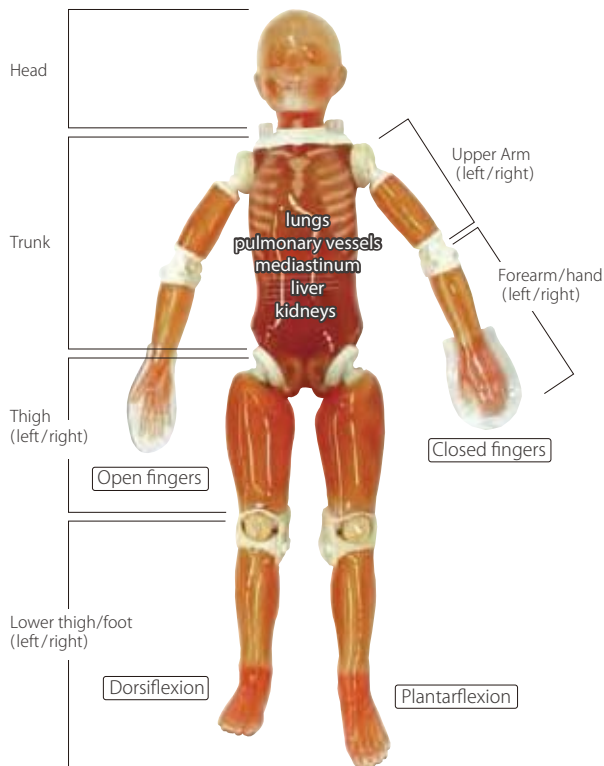
Plain X-ray



CT



PBU-70 phantom can be disassembled into 10 parts.



Main joints have close-to human articulation, allowing various positioning for training.

Shoulders with 360 degrees rotation  
Elbows bendable up to 90 degrees  
Hip joints allow over 180 degrees "leg split"  
Knees bendable up to 90 degrees

Frog leg position

### Specifications

Set Includes:  
1 pediatric whole body phantom: life-size, 5-year-old consists of 10 parts  
1 head supporter  
1 hand fixture belt  
1 set of sample X-ray images

Size:  
phantom height: approx. 110 cm  
phantom weight: approx. 20 kg  
approx. 43.3 inch approx. 40 lb.

Optional Parts:  
41303-060 storage case for PH-2C



PH-2D

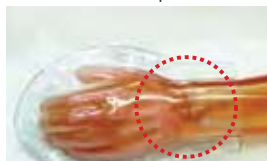## Bone Fracture Pediatric Phantom "PBU-70B" New

Training in pediatric radiography can be enriched with clear and subtle bone fractures. Typical fractures resulting from child abuse are also included.

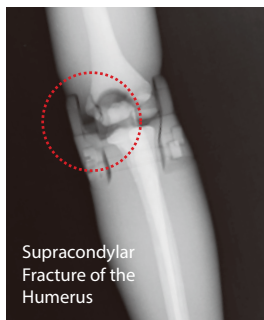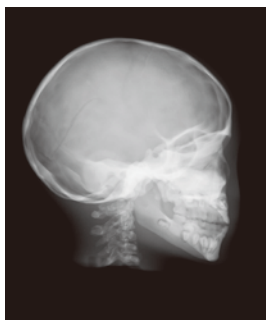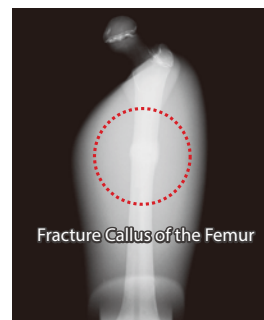
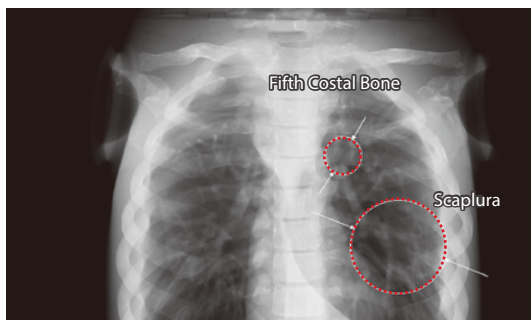
All fractures are prepared on the left side of the phantom.



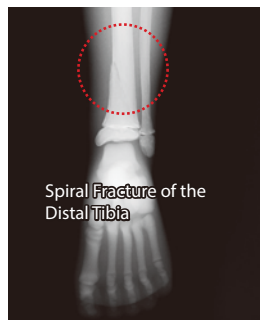
Spiral Fracture of the Distal Tibia



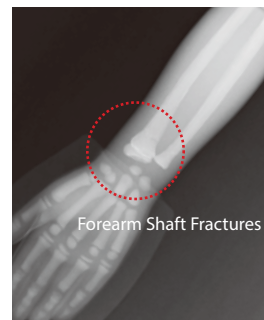
Forearm Shaft Fractures



Supracondylar Fracture of the Humerus



Spiral Fracture of the Distal Tibia



Forearm Shaft Fractures